

Molar Changes with Cervical Headgear Alone or in Combination with Rapid Maxillary Expansion

Marcel Marchiori Farret^a; Eduardo Martinelli S. de Lima^b; Vanessa Pereira Araújo^c; Susana Maria Deon Rizzato^b; Luciane Macedo de Menezes^b; Marcio Lima Grossi^d

ABSTRACT

Objective: To test the hypothesis that there is no difference in the distal movement of the maxillary first permanent molars when cervical headgear is used alone or in combination with rapid maxillary expansion.

Materials and Methods: The sample was composed of 36 subjects (aged 9 to 13 years), treated in the Faculty of Dentistry, Pontifícia Universidade Católica, Rio Grande do Sul, Brazil. The individuals were in good health and in their pubertal growth period. All had Class II division 1 malocclusion. The patients were divided into two groups: group 1 (22 subjects), Class II, with a normal transverse maxilla treated with cervical traction headgear (HG) 400 g 12 h/d, and group 2 (14 subjects), Class II maxillary transverse deficiency treated with rapid maxillary expansion plus cervical traction headgear (RME + HG). An additional group 3 (17 subjects) served as a control group and included individuals with the same characteristics. All subjects had two lateral cephalograms: initial (T1) and progress (T2), taken 6 months later. Differences between T1 and T2 were compared with the Student's *t*-test, and three groups were compared by the analysis of variance and Tukey multiple comparison test.

Results: Results showed greater distal tipping and greater distal movement of the first permanent molars in group 1 (HG) than in group 2 (RME + HG), $P < .05$. No extrusion of first permanent molar occurred in either group ($P > .05$).

Conclusion: The hypothesis was rejected. Cervical traction headgear alone produced greater distal movement effects in maxillary first permanent molars when compared with rapid maxillary expansion associated with cervical headgear.

KEY WORDS: Class II malocclusion; Cervical headgear; Rapid maxillary expansion

INTRODUCTION

Class II malocclusion is present in approximately 30% of the American population and may have different morphologic characteristics affecting dentoalveolar processes and basal bones.¹ An inadequate maxillo-mandibular relationship in the anterior-posterior and in the vertical directions can be associated with a trans-

verse maxillary deficiency, which may be masked by the sagittal discrepancy.²⁻⁵

Extraoral forces provided by headgear (HG) are considered the gold standard treatment of Class II malocclusions in growing patients.⁶ The principles of biomechanics determine the direction of the pull, the extents, and angulations of the outer bow.⁷⁻¹¹ Cervical traction is well accepted by patients, and many authors have demonstrated its efficacy, especially in hypodivergent and mesodivergent skeletal patterns.

Once a Class II division 1 malocclusion with a transverse maxillary deficiency is diagnosed, rapid maxillary expansion (RME) should be the first step of the treatment.¹²⁻¹⁴ The Haas expander has been widely used to correct this problem and shows good long-term stability.¹⁵⁻²⁰ The HG can be recommended even during expansion in adolescents, whose remaining growth of the mandible is essential for the correction of the sagittal discrepancy.

Both treatments (HG and RME) deliver forces to the maxillary first permanent molars, and changes in their positions are reflected in the maxillary and mandibular

^a Graduate PhD student, Department of Orthodontics, Pontifícia Universidade Católica, Rio Grande do Sul, Brazil.

^b Professor, Department of Orthodontics, PUCRS, Rio Grande do Sul, Brazil.

^c Graduate MS student, Department of Orthodontics, Pontifícia Universidade Católica, Rio Grande do Sul, Brazil.

^d Professor, Department of Prosthodontics, Pontifícia Universidade Católica, Rio Grande do Sul, Brazil.

Corresponding author: Dr Marcel Marchiori Farret, Department of Orthodontics, Pontifícia Universidade Católica, Av. Ipiranga, Porto Alegre, Rio Grande do Sul, Brazil (e-mail: marcelfarret@yahoo.com.br)

Accepted: October 2007. Submitted: August 2007.

© 2008 by The EH Angle Education and Research Foundation, Inc.

regions, as well in the facial proportions.²¹⁻²⁷ Klein⁹ observed distal tipping and extrusion of first molars when HG cervical traction was used and stated that it was related to the design of the force system. RME also tends to tip first molars buccally, since the force is applied below the center of resistance of these teeth.

The forces systems are different if the HG cervical traction is applied to the maxillary first molars alone or applied to the molars connected to other teeth by a Haas expander. Although the force magnitude and direction are similar, the center of resistance of the anchorage units is different, leading to different results. Furthermore, one could wonder if the HG cervical traction associated with RME would be as effective as used alone for maxillary first molar distal movement.

The aim of this study is to compare the effects of the HG cervical traction alone and in association with RME when applied to maxillary permanent first molars during the treatment of Class II malocclusion.

MATERIALS AND METHODS

The sample of this study was composed of 36 Class II division 1 patients (13 males and 23 females, aged 9 to 13 years) treated during the years 2004 and 2005 in the Clinic of Orthodontics, Faculty of Dentistry, Pontifícia Universidade Católica, Rio Grande do Sul, Brazil. All of the patients were white Brazilians and in good general and oral health. Selection criteria for subjects included being in the pubertal growth period, having a hypodivergent or mesodivergent skeletal pattern, having an overjet >4 mm, and crowding in the mandibular arch <3 mm. The diagnosis for maxillary transverse deficiency considered maxillary and mandibular first permanent intermolar distances (Figure 1). The control group included 17 Class I patients, aged 8 to 13 years, with the same general characteristics and treated only by space maintenance and/or diskling of deciduous canines. Treatment of all patients was under supervision of the same professor.

Initial records (T1) included medical and dental history, study models, a lateral cephalogram, and a hand and wrist radiograph. Skeletal age was determined according to Greulich-Pyle (males = 10.5 to 13 years and females = 9 to 11.5 years). Study models were used for diagnosis of the Class II division 1 malocclusion and of the transverse maxillary deficiency. First molars were required to present a cusp-to-cusp relationship as the minimum criteria for Class II. A transverse maxillary deficiency was determined when the maxillary intermolar distance was 4 mm smaller than the mandibular intermolar distance (Figure 1). The skeletal pattern was checked in the lateral cephalogram as GoGn.SN <38° for all patients. According to the orthodontic diagnosis, patients were allocated to

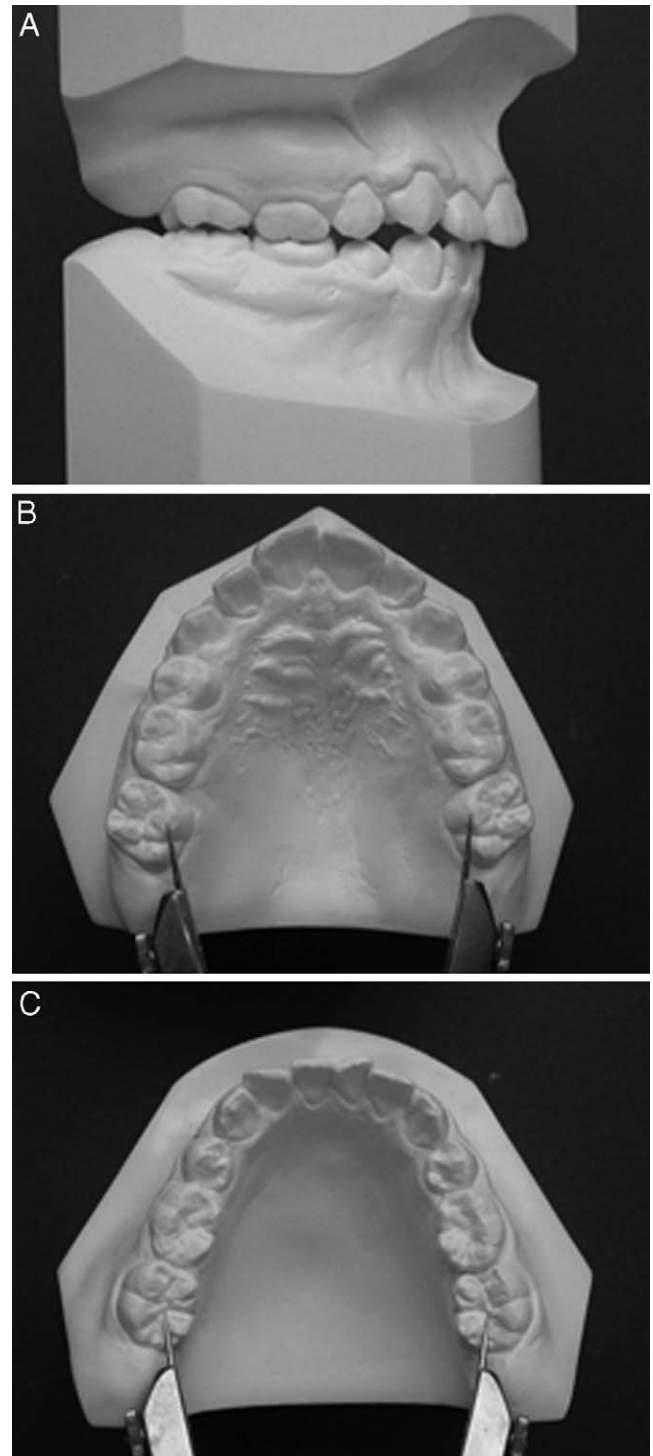


Figure 1. Analysis of the dental casts. (A) Class II molar relationship. (B) Maxillary intermolar distance. (C) Mandibular intermolar distance.

group 1 (Class II, normal transverse maxilla) or group 2 (Class II, maxillary transversal deficiency).

Patients in group 1 (6 males, 16 females) were treated with HG cervical traction with 400 g on each side 12 to 14 hours per day. The design of the HG cervical

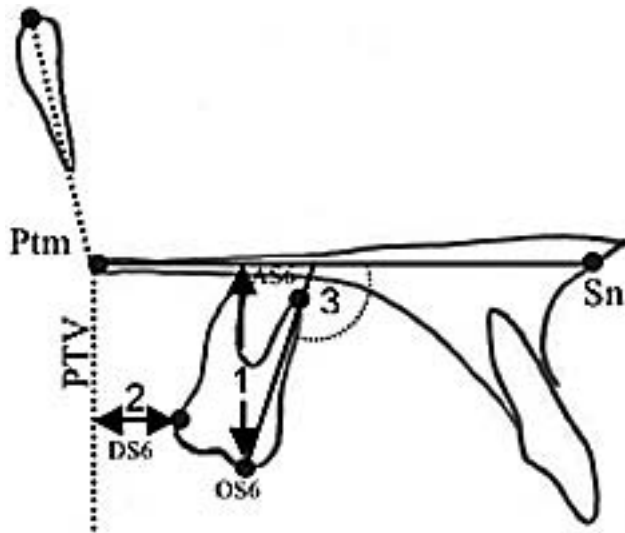


Figure 2. Anatomic tracings and cephalometric measurements. (1) Molar height: linear perpendicular distance from OS6 to palatal plane (Ptm-Sn). (2) Molar A-P: linear perpendicular distance from DS6 to line PTV. (3) Molar tip: angle between the long axis of the first permanent molar (AS6-OS6) and the palatal plane.

traction placed the outer bow parallel to the inner bow, ending at the region of the first molars. The inner bow was expanded 2 mm before insertion into the molar tubes. A Class I molar relationship was reached in 6 months (± 1 month).

Patients in group 2 (7 males, 7 females) received RME with a modified Haas expander banded to the first molars and bonded to the first premolars or first deciduous molars. The expander was activated four times on the first day and two times per day thereafter until a transverse overcorrection was reached. On the seventh day of expansion, patients of this group started using a HG, in the same manner as those of group 1. A Class I molar relationship was reached in 6 months (± 1 month).

In group 3 (controls), patients (8 males, 9 females) had a normal transverse maxilla and received minor orthodontic procedures, such as space maintenance and disking of deciduous teeth.

Follow-up records (T2) included lateral cephalograms taken about 6 months after the initial records. The cephalograms were traced manually, and the cephalometric points were digitalized in the software Dentofacial Planner Plus (DFP 2.0) to establish linear and angular measurements (Figure 2).

For statistical analysis, Student's *t*-test was used for comparison between T1 and T2. One-way analysis of variance and the Tukey multiple comparison test were applied to compare variations identified in each group.

RESULTS

A distal tipping and distal movement of the first permanent molars occurred in both experimental groups

Table 1. Means, Standard Deviations, Average Difference, and Student's *t*-Test Comparing Initial (T1) and Follow-up (T2) Values of Molars, Group 1 (Headgear)

Measurement	n	Mean	SD	Average Difference	P
Molar height, mm					
T1	22	20.3	2.2	0.3	.29
T2	22	20.6	2.6		
Molar A-P, mm					
T1	22	8.4	1.9	-2.5	.01*
T2	22	5.9	2.8		
Molar tipping, °					
T1	22	105.8	4.4	9.9	.01*
T2	22	115.8	9.8		

* Significant difference, *P* = .05.

(*P* < .01, Tables 1 and 2), which was not observed in the group 3 controls (*P* > .05, Table 3). These alterations were greater in group 1, which was treated with only HG (*P* < .01, Table 4).

DISCUSSION

The changes in maxillary first molar position are only part of a broader context of modifications related to Class II treatment. The approaches studied here (HG and HG + RME) can reach other structures, such as the maxilla and mandible and their relationship. Nevertheless, these effects were not studied here and will be discussed in later studies.

According to skeletal age, the patients were at the peak of pubertal growth, ranging from 1 year before and 1 year after peak. In this manner, gender differences were minimized, although they were not eliminated. Patients in group 2 had a transverse maxillary deficiency diagnosed when the maxillary intermolar distance was 4 mm smaller than the mandibular intermolar distance, which represented a transverse differ-

Table 2. Means, Standard Deviations, Average Difference, and Student's *t*-Test Comparing Initial (T1) and Follow-up (T2) Values of Molars, Group 2 (Rapid Maxillary Expansion + Headgear)

Measurement	n	Mean	SD	Average Difference	P
Molar height, mm					
T1	14	21.5	1.8	0.2	.39
T2	14	21.7	1.7		
Molar A-P, mm					
T1	14	7.6	2.2	-1.1	.05*
T2	14	6.4	2.0		
Molar tipping, °					
T1	14	106.0	3.8	3.1	.01*
T2	14	109.2	5.0		

* Significant difference, *P* = .05.

Table 3. Means, Standard Deviations, Average Difference, and Student's *t*-Test Comparing Initial (T1) and Follow-up (T2) Values of Molars, Group 3 (Control)

Measurement	n	Mean	SD	Average Difference	<i>P</i>
Molar height, mm					
T1	17	21.7	1.8	0.6	.02*
T2	17	22.3	2.2		
Molar A-P, mm					
T1	17	9.5	2.3	0.5	.21
T2	17	10.1	2.7		
Molar tipping, °					
T1	17	103.0	3.8	-0.7	.45
T2	17	102.3	3.5		

* Significant difference, *P* = .05.

ence. The patients in group 1 had a normal transverse maxilla. However, in both groups, patients had Class II division 1 malocclusion, and the study considered changes in the anterior-posterior direction.

The criteria of sample selection considered the skeletal pattern, avoiding hyperdivergent individuals in which HG cervical traction could produce undesired side effects such as molar extrusion. However, it should be noted that the design of the HG cervical traction made the outer bow parallel to the inner bow, and the outer bow ended at the first maxillary molar region. In this way, the vertical components of force were reduced, and less extrusion was expected. This approach may increase the indications for this kind of treatment to include some mild Class II problems with borderline vertical skeletal patterns.

Some authors considered that cervical traction HG treatment provokes extrusion of the anchoring molars, leading to clockwise rotation of the mandible and increases in the anterior facial height.^{7,21,12,24} The results obtained here with both treatment approaches did not show significant extrusion of maxillary molars during the period of the study. This disagreement may be related to the skeletal pattern of our sample and to the design of the HG.^{7,9} In the present study, the outer bow was made parallel to the inner bow and ended at the region of the first permanent molars. Such a design maximized the horizontal components of the force system and reduced the tendency for molar extrusion. Longer outer bows tend to increase vertical components in the force system, allowing greater extrusion of the maxillary molars.

Distal movement of the molars was more evident in patients treated with only HG. It should be remembered that the distal tipping contributed to this result. Treatment with HG + RME resulted in a smaller distal movement of molars but also lesser distal tipping. In

Table 4. Minimum and Maximum Differences, Means, Standard Deviations, and One-Way Analysis of Variance With Tukey Multiple Comparison Test Within Groups in the Two Time Periods Evaluated^a

Measurement	n	Difference (T2-T1)				<i>P</i>
		Minimum	Maximum	Mean	SD	
Molar height, mm						
HG	22	-2.2	3.7	0.3	1.3	.59
RME + HG	14	-1.8	2.1	0.2	1.0	
Control	17	-1.4	2.7	0.6	1.0	
Molar A-P, mm						
HG	22	-0.9	8.2	-2.5 ^A	2.2	.01*
RME + HG	14	-2.1	4.5	-1.1 ^{AB}	1.9	
Control	17	-3.3	2.3	0.5 ^B	1.7	
Molar tipping, °						
HG	22	-5.3	26.8	9.9 ^A	9.9	.01*
RME + HG	14	-0.6	11.6	3.1 ^B	3.3	
Control	17	-8.4	7.3	-0.7 ^B	3.7	

^a HG indicates head gear; RME, rapid maxillary expansion.

* Significant difference, *P* = .05. Mean values followed by the same letter do not differ.

this approach, the modified Haas expander formed a unity, resisting against the molar distal tipping.

In the design of the HG described in the present study, the forces passed below the center of resistance of the maxillary first molars, provoking significant distal tipping of these teeth. This condition is considered a step in comprehensive Class II orthodontic treatment and must be corrected in a later stage with full orthodontic fixed appliances. When the outer bow is superiorly inclined, as used by Gandini et al⁸ and Lima Filho et al,^{13,24} the force vector passes through the center of resistance of the first permanent molars, leading to a downward and backward translation. As extrusion is predictable with this design, and it is applied mainly to hypodivergent individuals.

From a clinical standpoint, both treatments studied (HG and HG + RME) were effective. On average, 6 months was all that was required to reach a Class I molar relationship. In group 1, treated only with HG cervical traction, the greater distal tipping of the first molars created a mesial gap, which suggested immediate bonding of brackets to the maxillary teeth for leveling and distal movement of premolars and canines. Patients in group 2 (HG + RME) showed less distal tipping and no space mesial to the first molars since the temporary molars or premolars were distalized together by their connection to the modified Haas expander. It must be emphasized that patients were very cooperative, and this played an important role in the results of this research.

CONCLUSIONS

- There was distal movement and distal tipping of the first maxillary permanent molars in both treatments (HG and HG + RME).

- The HG alone caused greater distal movement and distal tipping of the maxillary permanent first molar.
- There was no significant extrusion of maxillary permanent first molars in both treatments (HG and HG + RME).

REFERENCES

1. Angle H. Classification of malocclusion. *Dent Cosmos*. 1899;248–264.
2. Henry RG. A classification of Class II division 1 malocclusion. *Angle Orthod*. 1957;27:83–92.
3. Rosenblum RE. Class II malocclusion: mandibular retrusion or maxillary protrusion? *Angle Orthod*. 1995;65:49–62.
4. Silva Filho OG, Villas Boas MC, Capelozza Filho L. Rapid maxillary expansion in the primary and mixed dentition: a cephalometric evaluation. *Am J Orthod Dentofacial Orthop*. 1991;100:171–181.
5. Tollaro I, Bacetti T, Franchi L, Tanescu CD. Role of posterior transverse interarch discrepancy in Class II, division 1 malocclusion during the mixed dentition phase. *Am J Orthod Dentofacial Orthop*. 1996;110:417–422.
6. Johnston LE. Answers in search of questioners. *Am J Orthod Dentofacial Orthop*. 2002;21:552–553.
7. Armstrong MM. Controlling the magnitude, direction and duration of extraoral force. *Am J Orthod Dentofacial Orthop*. 1971;59:217–243.
8. Gandini MS, Gandini LG, Martins JCR, Del Santo M. Effects of cervical headgear and edgewise appliances on growing patients. *Am J Orthod Dentofacial Orthop*. 2001;19:531–539.
9. Klein PL. An evaluation of cervical traction on the maxilla and the upper first permanent molar. *Angle Orthod*. 1957;27:61–68.
10. Lima Filho RMA, Lima AL, Ruellas AC de O. Longitudinal study of anteroposterior and vertical maxillary changes in skeletal Class II patients treated with Klöehn cervical headgear. *Angle Orthod*. 2002;73:187–193.
11. Constasti GI, Legan HL. Biomechanical guidelines for headgear application. *J Clin Orthod*. 1982;16:308–312.
12. Lima Filho RMA, Lima AL. Long-term outcome of skeletal Class II division 1 malocclusion treated with rapid palatal expansion and Klöehn cervical headgear. *Am J Orthod Dentofacial Orthop*. 2003;124:216–224.
13. Lima Filho RMA, Lima AL, Ruellas AC de O. Spontaneous correction of Class II malocclusion after rapid palatal expansion. *Angle Orthod*. 2003;73:745–752.
14. Lima Filho RMA, Lima AL. Case report: long-term outcome of Class II division 1 malocclusion treated with rapid palatal expansion and cervical traction. *Angle Orthod*. 2000;70:89–94.
15. Fenderson FA, McNamara JA, Baccetti T, Veith CJ. A long-term study on the expansion effects of the cervical-pull face-bow with and without rapid maxillary expansion. *Angle Orthod*. 2004;74:439–449.
16. Haas AJ. Rapid expansion of the maxillary dental arch and nasal cavity by opening the midpalatal suture. *Angle Orthod*. 1961;31:73–79.
17. Haas AJ. The treatment of maxillary deficiency by opening the midpalatal suture. *Angle Orthod*. 1965;35:200–217.
18. Haas AJ. Palatal expansion: just the beginning of dentofacial orthopedics. *Am J Orthod Dentofacial Orthop*. 1970;57:219–255.
19. Haas AJ. Long-term posttreatment evaluation of rapid palatal expansion. *Angle Orthod*. 1980;50:189–217.
20. Haas AJ. Headgear therapy: the most efficient way to distalize molars. *Semin Orthod*. 2000;6:79–90.
21. Baumrind S, Molten R, West EE, Miller DM. Mandibular plane changes during maxillary retraction. *Am J Orthod Dentofacial Orthop*. 1978;74:32–40.
22. Wertz RA. Skeletal and dental changes accompanying rapid midpalatal suture opening. *Am J Orthod Dentofacial Orthop*. 1970;58:41–66.
23. Shimizu HR, Ambrosio AR, Shimizu JGB, Ribeiro JS, Staszak KR. Princípios biomecânicos do aparelho extra-bucal. *Rev Dentalpress de Orto e Ortop Facial*. 2004;9:122–156.
24. Lima Filho RMA, Lima AL, Ruellas AC de O. Mandibular changes in skeletal Class II patients treated with Klöehn cervical headgear. *Am J Orthod Dentofacial Orthop*. 2003;124:83–90.
25. Baumrind S, Molten R, West EE, Miller DM. Distal displacement of the maxilla and the upper first molar. *Am J Orthod Dentofacial Orthop*. 1979;75:630–640.
26. Cangialosi TJ, Meistrell ME, Leung MA, Ko JY. A cephalometric appraisal of edgewise Class II nonextraction treatment with extra-oral force. *Am J Orthod Dentofacial Orthop*. 1988;93:315–324.
27. Chung C, Font B. Skeletal and dental changes in the sagittal, vertical, and transverse dimensions after rapid palatal expansion. *Am J Orthod Dentofacial Orthop*. 2004;126:569–575.